Pediatric Plastic Surgery

Children's Hospital of Pittsburgh

A Rewarding Relationship

Dr. Losee shows Emmanuel, 6, the photographs he has taken of him.

Letter From the Chief

Dear Physician,

The Division of Pediatric Plastic Surgery at Children's Hospital of Pittsburgh is the region's leading center for the treatment of children with congenital and acquired deformities. As the chief of the division, I am enthusiastic about sharing with you the services we can provide your patients. The following pages highlight our strengths in a wide range of plastic surgery subspecialties.

As a cleft and craniofacial surgeon, I am privileged to serve as the director of the Cleft-Craniofacial Center. One of the nation's oldest interdisciplinary centers, it has more than 50 years of patient care experience.

Our philosophy in caring for this unique patient population includes providing our consultations and appointments in a smooth and timely fashion. Whenever you feel it necessary or have any question, I urge you to contact our office or the page operator to speak with the attending plastic surgeon on call.

We look forward to developing a rewarding working relationship with you to care for the pediatric patients in this area.

I send you my kindest regards,

Joseph E. Losee, MD, FACS, FAAP
Chief, Division of Pediatric Plastic Surgery
Director, Cleft-Craniofacial Center
Program Director, Craniofacial Fellowship and Plastic Surgery Residency
Children's Hospital of Pittsburgh

Full Spectrum of Specialties

Specialists in the Division of Pediatric Plastic Surgery are experienced in treating virtually any situation you may encounter in a patient, from conditions impairing function to appearance-related conditions with psychological effects.

Craniofacial Surgery

Craniofacial surgery is a subspecialty of plastic surgery that deals with the reconstruction of congenital and acquired anomalies of the soft and hard tissues of the head and neck. This field includes surgery for congenital and syndromic conditions such as fusion of the cranial sutures resulting in craniosynostosis and abnormal head shapes. Surgery for congenital facial deformities, such as hemifacial microsomia and orbital hypertelorism, can establish harmony and balance to the face and jaws. Craniofacial surgery for acquired deformities, such as facial fractures, dog bites and other traumatic injuries, allows one to restore both form and function.

Plastic surgeons, having completed a fellowship in craniofacial surgery, often work in concert with pediatric neurosurgeons to treat these challenging anomalies. Despite the low incidence of complications, these invasive procedures carry a potential for significant mortality and morbidity. This fact underscores the need for a dedicated surgical team that routinely works together performing a minimum of these surgeries annually. Our team consists of plastic surgeons, neurosurgeons, pediatric dentists, orthodontists, speech pathologists, psychologists, social workers, ENT surgeons, geneticists and others.

Sarah as a newborn with metopic craniosynostosis resulting in trigonocephaly.

Our team

consists of plastic surgeons, neurosurgeons, pediatric dentists, orthodontists, speech pathologists, psychologists, social workers, ENT surgeons, geneticists and others.

Sarah, now 3, after cranial vault remolding with normal craniofacial growth.

To facilitate the rapid and smooth consultation for any of your patients with cleft or craniofacial anomalies, or other unusual situations, contact our office to speak directly with one of the attending plastic surgeons — or call the Children's Hospital of Pittsburgh page operator at 412-692-5325 and have the attending plastic surgeon on call paged.

Stage-by-Stage Care

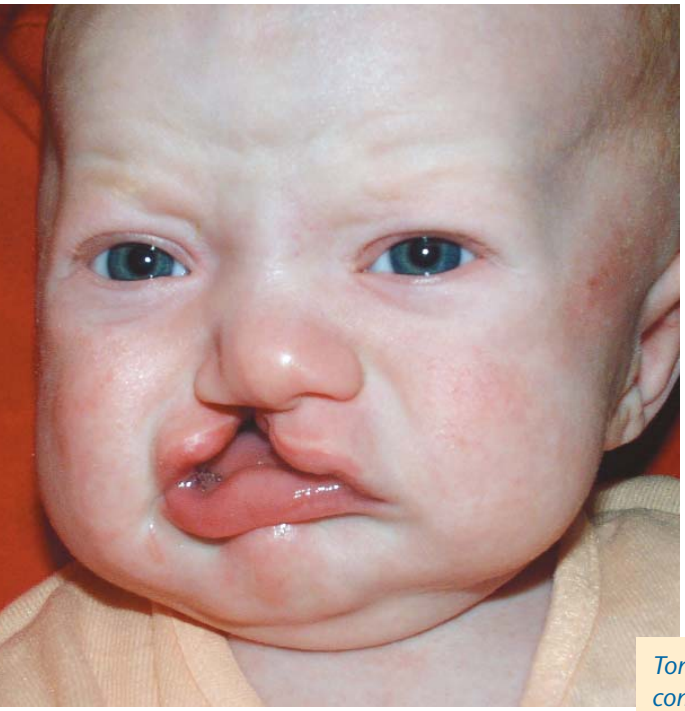

Cleft Lip and Palate

When the normal intrauterine development of the face is interrupted, a cleft of the lip and/or palate may occur. This anomaly may range from a small notch in the lip (incomplete cleft), to a complete bilateral cleft lip, nose and palate.

Pediatric plastic surgeons are uniquely trained to treat all stages of surgery your cleft patient will require — from the initial cleft lip repair to the final jaw surgery at skeletal maturity.

Tommy as a newborn with a right-sided complete cleft lip and palate.

Pediatric plastic surgeons are ***uniquely trained*** *to* ***treat all stages*** *of surgery your cleft patient will require.*

Tommy post-op from cleft lip and nose repair.

Orthodontics

Our division's pediatric craniofacial orthodontist works closely with our surgeons on many cleft, craniofacial and jaw surgery cases. The orthodontist prepares newborns with cleft lips for surgery by a process of nasoalveolar molding *(see photo)*. Nasoalveolar molding utilizes a presurgical infant orthopaedic appliance to reduce the severity of the cleft and deformity of the nose prior to surgery. In addition, the orthodontist plays a significant role in the complex long-term treatment planning for each cleft and craniofacial patient.

Orthodontic care is also provided through our division to create normal smiles and prepare patients for jaw surgery.

Top Left: *Adam at birth with a right complete unilateral cleft lip and palate.*

Bottom Left: *Adam undergoing nasoalveolar molding at six weeks.*

Above: *Adam at week 20 prior to primary lip/nose repair.*

Crafting, Correcting

Ear Surgery

Ear surgery, or otoplasty, is usually performed to set prominent ears closer to the head. Pediatric plastic surgeons recommend this surgery when the child is about 6 years old — the age when ears have reached adult size. An incision is made behind the ear to expose the ear cartilage. The cartilage is then sculpted to bend it back toward the head. Patients wear a light head dressing for a number of weeks after surgery.

Surgery also can be performed to correct a variety of other ear problems, such as a constricted ear, when the top of the ear folds downward, or microtia, when a child is born without complete ears.

Ben before surgery with bilateral prominent ears.

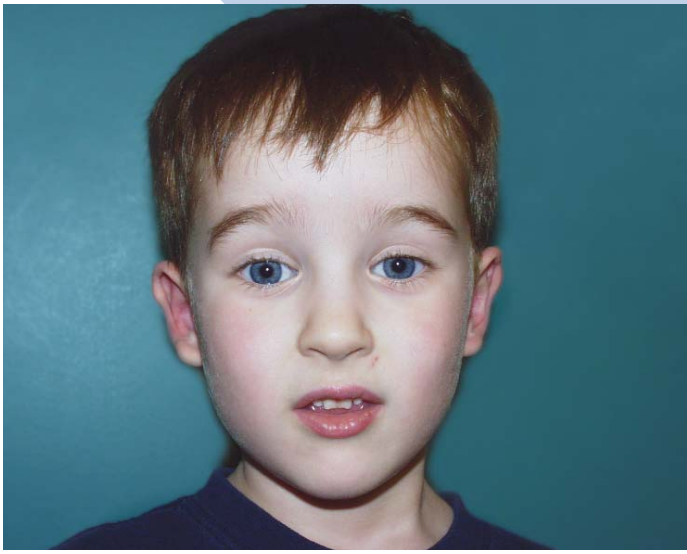

Ben one year after otoplasty.

Congenital Nevi (Moles)

Congenital moles, or nevi, are brown birthmarks found in up to 1 percent of all newborns. They are usually less than 1 centimeter in diameter, but, in rare cases, giant nevi can reach a diameter of 20 centimeters or more.

Giant nevi carry a significant risk of developing into melanoma. The exact increased risk of malignant transformation is controversial and still debated. Moles that are observed to change in color, texture or size should be examined routinely and possibly removed for diagnosis. Other considerations must be taken into account when considering removal, such as a family history of melanoma or when the lesions are in difficult-to-observe places on the body, such as the scalp.

Left: *An infant born with a giant congenital nevi of her right upper back and shoulder.*

Below Left: *The same child at 3, during active tissue expansion to prepare for surgery.*

Below Right: *The child after removal of tissue expanders, excision of nevus and closure with expanded skin flap.*

Vascular Anomalies (Vascular Malformations and Hemangiomas)

Hemangiomas are the most common vascular birthmarks, and usually appear within the first month of life as bright red or blue-purple spots on the skin. Hemangiomas typically proliferate or grow within the first 12 months of life and then slowly involute, or shrink. Most hemangiomas do not require treatment; however, if a hemangioma causes problems with vision, blocks the airway, or causes bleeding or infections, treatment may be needed. Possible interventions include steroids or surgery.

Vascular malformations, however, are usually seen in the nursery at birth, grow with the child and do not involute. Vascular malformations are classified by what type of vessels make up the malformation. Capillary malformations (port-wine stains) are effectively treated with a pulse-dye laser early in life. Lymphatic malformations (cystic hygromas) often are treated with surgery. Arterial and venous malformations often are treated with combined interventional radiology thrombosis and surgical resection.

Children born with vascular anomalies of all kinds are followed in our new interdisciplinary Vascular Anomalies Center at Children's Hospital.

Above right: *Guadaloupe as an infant born with a hemangioma of the left cheek that blocked her vision and placed her at risk for blindness from "disuse" amblyopia.*

Above: *Guadaloupe several months after high-dose systemic steroid therapy, resulting in "premature" involution of her hemangioma and preservation of her vision. Further reconstructive surgery can be considered as she grows and develops.*

Hand Surgery

Whether the defect is congenital or acquired, hand surgery attempts to improve hand function and appearance. Acquired defects include nerve injuries, tendon lacerations and fractures. Children born with syndactyly (webbed fingers) can benefit from finger separation with a zig-zag type incision to help prevent growth deformities. Children born with polydactyly (extra fingers) may benefit from simple removal of those fingers. Plastic surgery also can be used to help reconstruct fingers that are missing because of trauma or developmental defects.

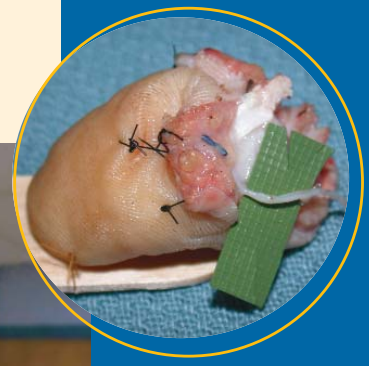

Re-Attaching a Thumb

WHEN TY WILDEY, 11 (ABOVE), CUT OFF HIS THUMB *in a log splitter in the fall of 2004, there seemed no chance that he would ever use it again. Rushed to Children's from his home in Connellsville, Pa., he was seen by Kodi K. Azari, MD, who had just arrived at Children's from the UCLA Medical Center. Ty was his first case at Children's.*

In an initial 10-hour surgery, Dr. Azari re-attached the thumb in an operation that approached the technical limits of microsurgery. Dr. Azari used veins from Ty's forearm to revascularize his thumb. Within months, Ty had nearly normal sensation and could fully oppose his thumb. In fact, he can grip and throw a football and is pitching a "mean" fast ball.

Above top: *Ty's hand before surgery.*

Above center: *The severed thumb before surgery.*

Above bottom: *Two months after surgery, the thumb can be opposed to all four fingers.*

From Discomfort to Trauma

Breast Surgery

Both boys and girls can suffer from disorders of the breast. In girls, macromastia (heavy, pendulous breasts) can cause physical discomfort. Neck and back pain, along with grooves in the skin of the shoulders caused by the pressure of brassiere straps, are common complaints. Excessively large breasts can be psychologically embarrassing and can limit a teenager's ability to interact with her peers. Breast reduction surgery usually is performed after breast growth is complete.

Boys also can suffer from a psychological and physical burden caused by gynecomastia (enlargement of the male breast). Up to 65 percent of boys experience some degree of gynecomastia during puberty that resolves spontaneously. If breast enlargement is persistent and causing a significant psychosocial problem, the adolescent male may benefit greatly from surgery.

General Reconstructive Surgery

Plastic surgeons also treat complex reconstructive problems that may occur as a result of trauma or tumors. Using specialized techniques, during hours of surgery under a microscope, plastic surgeons can reattach an amputated finger or transplant a flap — a section of tissue carrying its own blood supply — to help restore skin, muscle or bone that has been lost. Plastic surgeons often use these techniques to assist colleagues in other surgical disciplines.

Far Left: *Pre-operative photo of young boy with traumatic soft tissue defect of the left foot with exposed tendons and bones.*

Left: *Foot after limb salvage free tissue transfer from his abdomen, restoring form and function to his foot.*

Above: *Patient's abdominal donor site with acceptable scar and no functional disability.*

Personal Care

New patients at Children's Division of Pediatric Plastic Surgery receive a comprehensive examination to determine their conditions and evaluate their needs. After the visit, the findings and recommendations are communicated clearly to the family and primary care physician.

Advances in technology, including high-resolution ultrasonography and genetic testing, offer opportunities for diagnosis of some congenital problems even before birth. A prenatal consultation can help parents understand their child's condition and treatment options, and clarify their expectations.

A ***prenatal consultation*** *can* ***help parents understand*** *their child's condition and treatment options, and* ***clarify*** *their expectations.*

Referrals

Referral to the Division of Pediatric Plastic Surgery at Children's can be made by pediatricians, primary care physicians, obstetricians or other health professionals. Routine consultations and office visits can be arranged through our division's schedulers by calling 412-692-8650.

Should you have any question or an unusual consultation, we urge you to call our office physician line (412-692-3402) and ask to speak directly with an attending pediatric plastic surgeon. We also can be contacted directly through Children's Hospital page operators (412-692-5325).

Moving Forward

Responding to increasing demand for its many pediatric services and research programs, Children's Hospital is building a new 1.4-million-square-foot campus, scheduled to open in the Lawrenceville section of Pittsburgh in 2009.

An Experienced Team

Kodi Azari, MD, is an assistant professor of plastic surgery at the University of Pittsburgh School of Medicine and is the associate director of the hand and upper extremity fellowship. He came to Children's Hospital of Pittsburgh after completing a hand and microsurgery fellowship and services as a clinical instructor in orthopaedic surgery and plastic surgery at the UCLA Medical Center. Prior to that, Dr. Azari completed a residency in general surgery and plastic surgery at the University of Pittsburgh Medical Center (UPMC) and a tissue engineering fellowship at Carnegie Mellon University.

Dr. Azari earned his medical degree from East Carolina University School of Medicine in Greenville, N.C., in 1997 after graduating from the University of Connecticut with a bachelor's degree in biological sciences. His research work includes published papers on bone regeneration, tissue engineering and muscular, skeletal and neuronal reconstruction.

Frederic White-Brown Deleyiannis, MD, MPhil, MPH, is an assistant professor of plastic surgery at the University of Pittsburgh School of Medicine. He completed training in aesthetic, plastic and reconstructive surgery at the University of Pittsburgh and is a graduate of the University of Pennsylvania, Yale University School of Medicine and the University of Cambridge. He is board-certified both by the American Board of Plastic Surgery and by the American Board of Otolaryngology — Head and Neck Surgery. He has completed fellowship training at the University of Oviedo in Spain and has published more than 25 articles and book chapters about plastic surgery, head and neck surgery, and cleft and craniofacial surgery.

Shao Jiang, MD, is a member of the Division of Plastic Surgery at the University of Pittsburgh. He received both his bachelor's and medical degrees from the Pennsylvania State University. He completed training in general surgery and plastic and reconstructive surgery at the University of Rochester Strong Memorial Medical Center. After his residency, he completed the pediatric plastic and craniofacial surgery fellowship at Children's Hospital of Pittsburgh. Following this, he did additional training in orthognathic surgery at Childrens Hospital Los Angeles and held an academic appointment at the University of Southern California Division of Plastic and Reconstructive Surgery. Dr. Jiang's clinical interests include general pediatric plastic and reconstructive surgery, cleft lips and palates, as well as other congenital deformities. His research focuses on molecular biology of craniofacial anomalies.

A Rewarding Relationship

W.P. Andrew Lee, MD, FACS, is professor of surgery, chief of the Division of Plastic Surgery and director of the Hand Surgery Fellowship at the University of Pittsburgh School of Medicine. Dr. Lee came to Children's in 2002 after more than a decade at Massachusetts General Hospital in Boston, where he was chief of the hand surgery service in the Department of Surgery and director of the Plastic Surgery Research Laboratory. He also was director of the hand and microvascular surgery fellowship.

Dr. Lee graduated from Johns Hopkins University School of Medicine in 1983 after receiving a bachelor's degree in physics from Harvard University in 1979. After residencies in surgery at Johns Hopkins until 1989, he completed a residency in plastic surgery at Massachusetts General from 1989 to 1991. His research has been focused on transplant tolerance to composite tissue allografts such as a hand.

Joseph E. Losee, MD, FAAP, FACS, is currently division chief of Pediatric Plastic Surgery at Children's Hospital of Pittsburgh and director of the Pittsburgh Cleft-Craniofacial Center, with appointments in the departments of Surgery and Pediatrics. Dr. Losee completed his medical school training at the University of Rochester, where he also completed a residency in general surgery and plastic surgery. Following his residency, he went to the University of Pennsylvania and the Children's Hospital of Philadelphia for a fellowship in craniofacial surgery. After completing his training, he served as an attending surgeon and director of the Strong Center for Craniofacial Anomalies at the University of Rochester.

Dr. Losee also functions as program director of the plastic surgery residency and craniofacial fellowship. Dr. Losee's clinical focus is on children born with congenital deformities, including clefting and craniofacial anomalies. His research focuses on several areas within cleft and craniofacial surgery.

Lisa Vecchione, DMD, MDS, is director of orthodontic services at Children's Cleft-Craniofacial Center. She has appointments as assistant clinical professor of plastic surgery in the University of Pittsburgh School of Medicine and assistant professor in the Department of Orthodontics and Dentofacial Orthopedics in Pitt's School of Dental Medicine. She came to Children's in 2004 after a fellowship in cleft-craniofacial orthodontics at the Institute of Reconstructive Plastic Surgery at New York University. She received a master of dental science degree in 2003 from the Pitt School of Dental Medicine's Department of Orthodontics. She graduated summa cum laude with a doctor of medical dentistry degree from Pitt's School of Dental Medicine in 2000.

Dr. Vecchione graduated from the University of Pittsburgh at Bradford in 1993 with a bachelor's in chemistry after earning a bachelor's in medical illustration in 1989 at the Rochester Institute of Technology. She maintains a freelance career as a medical illustrator, creating computer graphics and illustrations of surgical procedures. Dr. Vecchione is principal or co-principal investigator in several research studies, including studies into the roles of the muscle fiber characteristics in facial morphology.

Children's Hospital of Pittsburgh
Division of Pediatric Plastic Surgery
3705 Fifth Avenue
Pittsburgh, PA 15213-2583

www.chp.edu

Photographers: Ronald Fontana, Donald Koch, Lisa Kyle, Annie O'Neill | Medical photographs are courtesy of Children's physicians. | BC/JY 04/05 04-618 5M RP